

# The incidence of complications in orthognathic surgery: A retrospective study

---

**Ravlić, Iva; Cerović, Robert; Mady Maričić, Barbara**

*Source / Izvornik:* **Medica Jadertina, 2024, 54, 121 - 128**

**Journal article, Published version**

**Rad u časopisu, Objavljena verzija rada (izdavačev PDF)**

<https://doi.org/10.57140/mj.54.2.7>

*Permanent link / Trajna poveznica:* <https://um.nsk.hr/um:nbn:hr:267:837284>

*Rights / Prava:* [In copyright](#)/[Zaštićeno autorskim pravom.](#)

*Download date / Datum preuzimanja:* **2024-09-14**

*Repository / Repozitorij:*

[Repository of General County Hospital Požega](#)

## The incidence of complications in orthognathic surgery: A retrospective study

*Učestalost komplikacija u ortognatskoj kirurgiji: retrospektivna studija*

Iva Ravlić, Robert Cerović, Barbara Mady Maričić\*

---

### Summary

**Objective:** The aim of this study was to analyze the type, frequency, treatment options and prevention methods of complications arising after surgical treatment of maxillofacial deformities.

**Methods:** This retrospective study was conducted using 72 medical records of Caucasian subjects who underwent surgery in 2018 and 2019 at the Clinic of Maxillofacial and Oral Surgery at Rijeka University Hospital Center. Intraoperative and postoperative complications were recorded.

**Results:** Most of the patients experienced some kind of complication and in most cases they were transitory. The consequences of damage to the sensory branches of the trigeminal nerve (occasional tingling, tightness, pain, loss of sensation) remain permanently present in most of the patients. The highest percentage of patients underwent surgical treatment due to speech and mastication problems. The majority of them are satisfied with the outcome.

**Conclusion:** Most of the complications can be successfully treated.

**Key words:** dentofacial deformities; orthognathic surgery; paresthesia; postoperative complication.

---

### Sažetak

**Cilj:** Cilj ove studije bio je analizirati vrstu, učestalost, način liječenja i metode prevencije komplikacija nastalih nakon kirurškog liječenja maksilofacijalnih deformiteta.

**Metode:** Ova retrospektivna studija provedena je analizirajući medicinske nalaze 72 bolesnika koji su bili podvrgnuti ortognatskim kirurškim zahvatima na Klinici za maksilofacijalnu i oralnu kirurgiju KBC Rijeka u 2018. i 2019. godini. Zabilježene su intraoperativne i postoperativne komplikacije.

**Rezultati:** Većina bolesnika imala je neku od komplikacija i u većini slučajeva te komplikacije su bile prolaznog karaktera. Posljedice u vezi s oštećenjem grana *n. trigeminusa* u većini bolesnika ostale su trajno prisutne. Najveći dio bolesnika podvrgnuo se operativnom zahvatu radi problema s govorom i žvakanjem. Većina bolesnika zadovoljna je ishodom.

**Zaključak:** Većina komplikacija može se uspješno liječiti.

**Ključne riječi:** dentofacijalni deformiteti; ortognatska kirurgija; parestezija; postoperativna komplikacija.

*Med Jad 2024;54(2):121-128*

### Introduction

Dentofacial deformities can be treated orthodontically, surgically or using a combination of both of the methods. The choice of method depends on the type and extent of the deformity. Surgical

treatment is usually approached after the end of bone growth (usually around ages 14 to 16 years for females and ages 17 to 21 years for males).<sup>1,2</sup>

Complications can be divided into complications related to the anesthesia and those related to the surgical part, as well as intraoperative and

---

\*Požega General Hospital, Otorhinolaryngology Department (Iva Ravlić, MD); University of Rijeka, Faculty of Medicine, Clinic of Maxillofacial and Oral Surgery (Robert Cerović, MD, PhD); University of Rijeka, Faculty of Dental Medicine, Department of Orthodontics (Barbara Mady Maričić, MD, PhD)

Correspondence address/ Adresa za dopisivanje: Iva Ravlić, MD, General Hospital Požega, Osječka 107, 34 000 Požega, Republic of Croatia E-mail: [iva.ravlic00@gmail.com](mailto:iva.ravlic00@gmail.com)

Primljeno/Received 2023-12-27; Ispravljeno/Revised 2024-05-13; Prihvaćeno/Accepted 2024-05-14

postoperative complications.<sup>3</sup>

Orthognathic surgery is performed under general anesthesia. Complications associated with general anesthesia can be divided into systemic (cardiovascular, respiratory, neurological, renal, anaphylactic shock, malignant hyperthermia, succinylcholine-induced apnea, postoperative nausea, and vomiting) and local (sore throat and dental injuries).

Intraoperative surgical complications are hemorrhage and segment fractures. Postoperative surgical complications can be relapse, neurological injury, neuropathic pain, change in nasal morphology, disorder of temporomandibular joint, bone necrosis, delay or nonunion of bone segments, infection, respiratory failure, trigeminocardiac reflex, pseudoaneurysm of the maxillary, facial and inferior alveolar artery, vomero-sphenoid disarticulation, dry eye, blindness, dental injury, benign paroxysmal positional vertigo, venous thromboembolism, otitis media, hearing problems and negative psychological effects. The most severe complication described in literature is the death of patients during or after surgery.<sup>4</sup> In the period from 2000 to 2016, 14 cases of patient deaths related to jaw surgery in Korea were recorded in a study. In two patients the cause of death was excessive bleeding, in four patients respiratory complications occurred (airway obstruction or respiratory insufficiency), in two patients causes were problems related with general anesthesia (one case is suspected to be due to malignant hyperthermia), brain damage by malpractice was a cause of death in one patient and five patients died of an unknown cause. The author states that there are around 5000 cases of orthognathic surgery performed every year in South Korea, which means that the mortality rate was about 0.005%.<sup>5</sup> Surgical procedures are divided into procedures on the upper and lower jaw. Procedures on the lower jaw are bilateral sagittal osteotomy (BSSO) and genioplasty, while maxilla osteotomy at the level of Le Fort I (LFOI) is the most common procedure on the upper jaw. Bimaxillary osteotomy (BMO) includes the osteotomy of both the upper and lower jaw. Distraction osteogenesis is a procedure that is accessed during the growth of the viscerocranium.<sup>2</sup>

### Patients and Methods

A retrospective study was conducted on 72 patients (51 female, 21 male) with the mean age of 26.28±9.65 years (range 16-66 years). They underwent orthognathic surgery in 2018 and 2019 at the Clinic of Maxillofacial and Oral Surgery at Rijeka University Hospital Center. The data was obtained

using medical records of patients and at medical check-ups. The patients were followed up for a period of 15 months to 3 years after surgery. The following independent variables were collected: sex, age, orthodontic preparation, extraction of third molars, duration of consumption of puréed diet, weight before and after the surgery, type, duration and treatment of surgical and postsurgical complications, reasons for undergoing surgery, patients satisfactory with the outcome and what was the worst consequence of the surgery for the patients. The results were analyzed with the IBM SPSS Statistics V27 statistical program. Data are expressed as percentages for nominal variables and means with standard deviations or medians with ranges for continuous variables.

### Results

In this study, 87.5% of patients (n=63) underwent orthognathic treatment and in 90.3% of patients (n=65) third molars were extracted prior to surgery.

The reasons for undergoing surgery were problems with mastication and speech in 53% of patients (n=38), both mastication and speech problems and dissatisfaction with aesthetic appearance in 42% of patients (n=30) and dissatisfaction with aesthetic appearance alone in 5% of patients (n=4).

Considering the satisfaction of patients with the outcome, 90% of patients (n=65) were satisfied, 6% of patients (n=4) were partially dissatisfied and 4% of patients (n=3) were dissatisfied.

The results obtained by answering the question on what patients think was the worst consequence of the surgery are presented in Table 1, with the largest percentage of the patients answering that eating puréed diet was the worst.

Patients consumed puréed diet for a period up to 6 months with a mean period of 2.075±1.16 months. Weight loss ranged from 0% to 31.4%, with a mean of 9.121±5.56 %.

The percentage of the patients that had some kind of complication was 93% (n=67). One patient (1.5%) had only anesthetic complications, 40.3% of patients (n=27) had surgical and anesthetic complications, while 58.2% of patients (n=39) had only surgical complications. Anesthetic complications were nausea (n=27, 37.5%), vomiting (n=19, 26.4%) and intraoperative and postoperative hypertension (n=1, 1.4%).

Postoperative complications are presented in Table 2, displaying that the most common postoperative complications were the need for material extraction, postoperative unacceptable jaw

position and pain.

Postoperative paresthesias occurred in 86.1% of patients (n=62), and the consequences related to the damage of the sensory part of the trigeminal nerve remained permanently present in 66.1% of patients (n=41).

Table 1 Patients answers to the question “What was the worst consequence of the surgery?”

Tablica 1. Odgovori pacijenata na pitanje „Koja je bila najgora posljedica operacije?”

Answers/ Odgovori	n	%
<b>Puréeed diet/ Pureed dijeta</b>	27	37.5
<b>Nothing/ Ništa</b>	13	18.1
<b>Inability to open the mouth Nemogućnost otvaranja usta</b>	7	9.7
<b>Vomit/ Povraćanje</b>	4	5.6
<b>Speech problems Problem govora</b>	4	5.6
<b>Pain/ Bol</b>	4	5.6
<b>Paresthesia/ Parestezija</b>	3	4.2
<b>Swelling/ Otok</b>	3	4.2
<b>Weakness/ Slabost</b>	3	4.2
<b>Material extraction Ekstrakcija materijala</b>	1	1.4
<b>Waking up from anesthesia Buđenje iz anestezije</b>	1	1.4
<b>Difficulty breathing Poteškoće kod disanja</b>	1	1.4
<b>Difficulty maintaining hygiene Poteškoće u održavanju higijene</b>	1	1.4

Table 2 Type and frequency of postoperative complications (multiple answer possibility)

Tablica 2. Vrsta i učestalost postoperativnih komplikacija (mogućnost više odgovora)

Complications/ komplikacije	n	%
<b>Material extraction Ekstrakcija materijala</b>	17	23.6
<b>Unfavorable jaw position Nepovoljan položaj čeljusti</b>	14	19.4
<b>Pain/ Bol</b>	13	18.1
<b>Material protrusion Prodor materijala</b>	12	16.7
<b>Infection Infekcija</b>	11	15.3

Complications/ komplikacije	n	%
<b>Localized edema Lokalizirani edem</b>	10	13.9
<b>Wound dehiscence Dehiscencija rane</b>	8	11.1
<b>Bleeding and hematoma Krvarenje i hematom</b>	5	6.9
<b>Fistula/ Fistula</b>	5	6.9
<b>Labial incompetence Labijalna nesposobnost</b>	5	6.9
<b>Dental problems Problemi sa zubima</b>	4	5.6
<b>Clicking jaw Klikanje čeljusti</b>	3	4.2
<b>Snoring Hrkanje</b>	2	2.8
<b>Deviated septum Devijacija septuma</b>	2	2.8
<b>Difficulty opening the mouth Otežano otvaranje usta</b>	2	2.8
<b>Speech problems Problem govora</b>	2	2.8
<b>Sinus infection Infekcija sinusa</b>	2	2.8
<b>Mandible deviation Devijacija donje čeljusti</b>	1	1.4
<b>Alopecia Alopecija</b>	1	1.4
<b>Difficulty chewing Poteškoće sa žvakanjem</b>	1	1.4

The mean duration of paresthesias in those patients who did not have permanent consequences of nerve damage was  $5.75 \pm 3.796$  months (range 1-18 months).

Areas on the face where paresthesias were present in the postoperative period are presented in Figure 1. Most of them were present in the chin and in lower lip area.

Figure 2 presents the areas of the permanent consequences of damage to the sensory branches of the trigeminal nerve. The chin area was mostly affected. Relapse occurred in 27.8% of patients (n=20), 45.8% of patients (n=33) did not relapse, while for 26.4% of patients (n=19) it is unknown whether relapse occurred because they did not come for regular check-ups.

Figure 3 presents types of relapses (7 patients had a combination of malocclusion). The highest percentage of patients underwent bimaxillary osteotomy (81.9%), while the least common procedure was osteogenesis distraction of the mandible (1.4%). The results are presented in Figure 4.

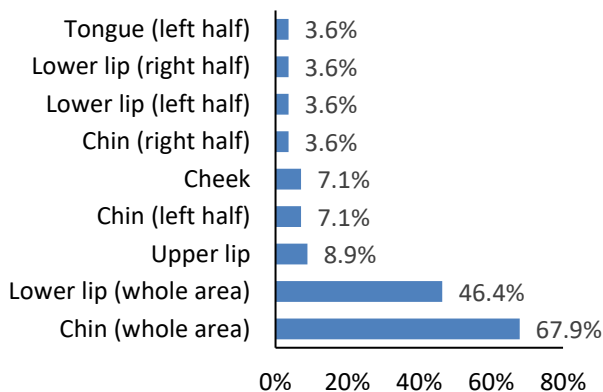


Figure 1 Areas on the face where paresthesias were present in the postoperative period  
 Slika 1. Područja na licu gdje su bile prisutne parestezije u postoperativnom razdoblju

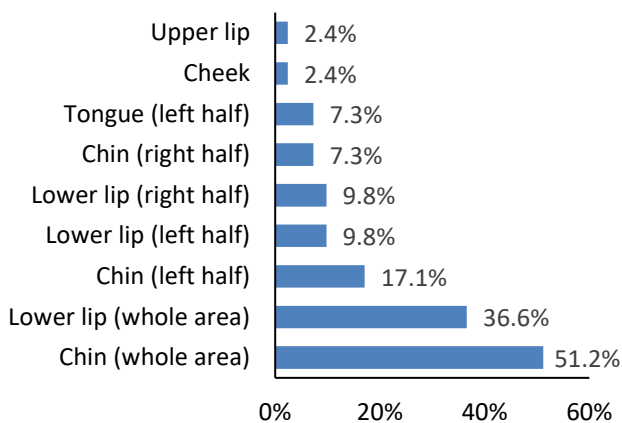


Figure 2 Areas on the face where paresthesias were present permanently  
 Slika 2. Područja na licu gdje su parestezije bile trajno prisutne

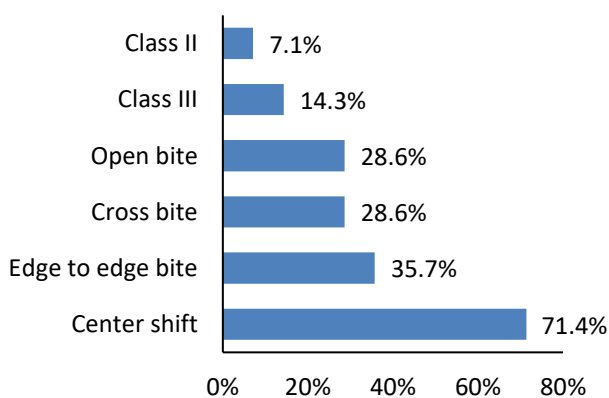


Figure 3 Types of relapses  
 Slika 3. Vrste recidiva

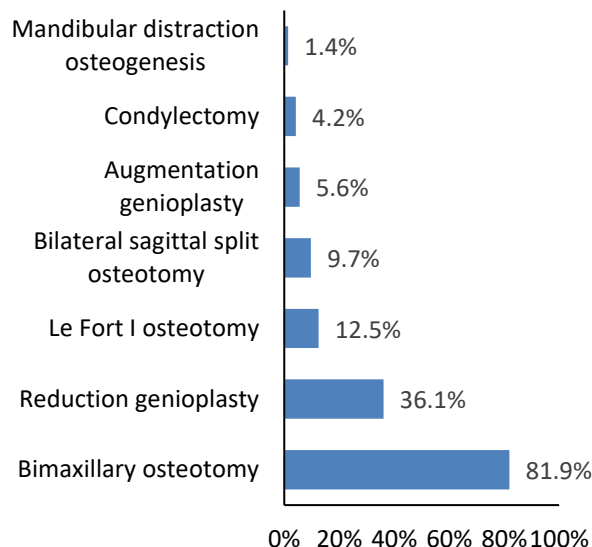


Figure 4 Procedure  
 Slika 4. Postupak

### Discussion

Most of the patients from this trial underwent third molar extraction in the period of 4 to 6 months prior to surgery, while a small percentage had third molars extracted during the surgery. In some patients there was no need for the extraction since the lack of individual teeth in the upper and lower jaw in some allowed preoperative orthodontic preparation for the third molar to move outside the anatomical region through which the bone section passes. None of the patients had an unfavorable fracture. Literature states that the reasons for third molar extraction include the reduced risk of developing postoperative infection, adverse osteotomy, and postoperative discomfort in patients.<sup>6</sup> Bone sections in bilateral sagittal split osteotomy (BSSO) and LeFort I osteotomy (LFOI) pass through the anatomical region in which the third molars are located.<sup>7</sup> Third molars can be extracted before or during surgery.<sup>3</sup> Literature mentions that the risk of unwanted fractures ranges from 0.94% to 3.2% if the third molars are removed simultaneously with BSSO.<sup>8</sup> Schwartz recommends the removal of third molars 6 to 9 months before BSSO in order to reduce the risk of adverse fractures and shorten the duration of surgery.<sup>9</sup> He also states that the presence of an empty pocket in which the third molar was located limits the positioning of the fork and plate due to thinning of the compact bone tissue, leading to unfavorable fixation.<sup>9</sup> On the other hand, Mehra, Doucet and Bouchard state that BSSO performed simultaneously with third molar extraction does not increase the risk of infection, fracture and unfavorable "split" and does not prolong the duration

of surgery.<sup>10-12</sup> Precious et al. state in a study conducted on 1256 patients who underwent BSSO the occurrence of an unfavorable fracture in 1.9% of patients (n=24).

Five patients underwent third molar extraction during BSSO, and 19 patients 6 months before BSSO.<sup>20</sup> Sasaki et al. recommend third molar extraction concomitantly with BSSO to reduce stress in patients and avoid waiting times between third molar extraction and orthognathic procedure.<sup>13</sup>

In the survey most of the patients (53%) stated that they had undergone surgery due to problems with mastication and speech. Brons et al. state in their study conducted on 24 patients with mandibular micrognathism that 54% of patients (n=13) had undergone the procedure due to dissatisfaction with aesthetic appearance. Patients who had undergone surgery for aesthetic reasons later developed functional problems.<sup>14</sup>

It is visible from the results that most patients (90%) are satisfied with the outcome of the operation. A small number of patients are dissatisfied (4%). Patients who are dissatisfied with the outcome of the operation criticize the unfavorable position of the mandible after surgery, a bite that is not fully adequate and the permanent consequences of nerve damage. Patients who expressed complete satisfaction reported a significant improvement in masticatory function and improved self-confidence. Takatsuji et al. state in a study conducted on 119 patients who had undergone orthognathic surgery that 8% of patients were dissatisfied with the outcome of the operation. They claimed that the reason for dissatisfaction was not the surgeon's skill, but the patient's psychological problems.<sup>15</sup> Türker et al. claimed that orthognathic surgery increases self-confidence and improves patients physical functioning.<sup>16</sup>

When asked what they considered was the worst consequence of the surgery, the largest percentage of patients answered that eating puréed diet and the inability to open their mouth was the biggest problem. Intermaxillary fixation creates the most difficulties for patients.

In an average duration of puréed diet of 2,075 months, patients lost an average of 9.121% of body weight. A puréed diet is generally recommended for 4 to 6 weeks.<sup>17</sup> All patients were prescribed a high-calorie protein energy drink (1.5 kcal/ml) for the specified period.

Hammond et al. stated that patients decreased their body fat percentage by an average of 3.07% over a 4-week observation period, while according to the rest of the literature, the usual loss of total body weight after jaw deformity surgery was 4-8%.<sup>18-19</sup>

Most of the patients had some complications. Despite prophylactic therapy (metoclopramide) 37.5% of patients had postoperative nausea and 26.4% of patients vomited after surgery.

Philips et al. conducted a study on 204 patients who had undergone orthognathic surgery and concluded that 67% of patients had postoperative nausea and 27% vomited in the postoperative period. Risk factors for nausea and vomiting include female gender, younger age, history of nausea while driving, duration of surgery and postoperative opioid administration.<sup>20</sup>

One patient developed hypertension (RR = 180/120 mmHg) during surgery and in the early postoperative period without signs of organ damage. He had no history of hypertension or risk factors, and did not develop it after the recovery period. Causes of hypertension in the intraoperative and early postoperative period may be sympathetic stimulation due to pain, hypothermia, hypoxia, intravascular volume overload due to excessive intravenous fluid administration during surgery and postoperative mobilization of fluid from extravascular spaces.<sup>21</sup> Literature mentioned the case of a patient who developed high hypertension during surgery and in the postoperative period (RR=299/145 mmHg) because of the undiagnosed pheochromocytoma.<sup>22</sup> Those findings are contradictory to the rest of the literature which states that blood pressure is usually lowered during maxillofacial surgery.<sup>23</sup>

Unsatisfactory postoperative jaw position was observed in 14 patients. In one patient, the displacement was repaired orthodontically, while in the others it was necessary to repeat the operation. The frequency of corrective procedures was not related to the type of deformity and surgery.

Five patients developed bleeding and hematomas. Two patients developed hematomas that spread from the cheek area to the chest and were successfully treated with topical

Heparin. One patient developed wound bleeding after dehiscence (spontaneously ceased) while two patients developed postoperative epistaxis. The development of a hematoma is considered as a minor complication but if a hematoma develops in the area of the bottom of the oral cavity, airway obstruction may occur.<sup>24</sup>

Eleven patients (15.3%) developed some form of infection after surgery. The patients received 1 g of intravenous cefazolin, 500 mg of metronidazole or 600 mg clindamycin 600 mg. Infections occurred most often in the area of wound dehiscence and in the area above the osteosynthesis material. Osteomyelitis of the mandible, otitis media, gingivitis, and peri mandibular abscess were less common. Infections

occurred in the period of two weeks to six months after surgery. *Escherichia hermannii* and *Peptostreptococcus* species were diagnosed as the causative agents. Cousin et al. state that infections in the area of the surgical site in orthognathic surgery occur in the range of 1.4% to 33.4%, and the most common type of infection is cellulitis.<sup>25</sup> Davis et al. in a study conducted on 2521 patients found an infection rate of 8%.<sup>26</sup>

In two patients, snoring occurred for the first time after surgery. Both patients had mandibular prognathism, and in one patient snoring occurred with septal deviation. Snoring can occur due to a change in the position of the tongue bone, which occurs as a result of a change in the position of the mandible during surgery, leading to narrowing of the airway.<sup>3,27</sup> Studies have shown that orthognathic surgery does not significantly affect the occurrence of snoring.<sup>3</sup>

Four patients experienced dental problems after surgery (pain when brushing teeth, necrosis of the pulp of the lower anterior incisor, gingival recession, and a much higher incidence of caries). A possible cause is inadequate oral hygiene during the period of intermaxillary fixation. Weinspach et al. discovered statistically significant increase in periodontal pocket formation after orthognathic procedures.<sup>28</sup> The incidence of pulp necrosis is higher in the maxilla.<sup>29</sup>

Septal deviation occurred in two patients after surgery. In one patient, the deviation was surgically managed while in other spontaneous recovery occurred. Causes of deviation may be changes in maxillary position, endotracheal intubation and septal cartilage dislocation due to incompletely emptied balloon during extubation.<sup>3,24</sup>

Fistula developed in the late postoperative period in five patients. Smaller fistulas in the area of the surgical suture and screws formed in most cases, while in one patient there was the development of oroantral fistula after extraction of surgical material.

Most patients experienced pain, most often in the area above the osteosynthesis plates and in the angle of the mandible. The pain occurred in the period from 4 to 8 months after the operation and stopped spontaneously or after extraction of the osteosynthesis material.

Two patients had limited mouth opening and were prescribed exercises. In one patient, mouth opening is still limited.

Five patients had transient labial incompetence. Labial incompetence occurs in patients with a prolonged vertical dimension.

Temporomandibular joint (TMJ) snapping occurred in three patients. Some studies claim that surgical correction of maxillary deformities may worsen TMJ disorders, while other studies claim that

it may improve them.<sup>3</sup>

Wound dehiscence occurred in 8 patients and was successfully managed with re-suturing and antibiotic therapy. The study conducted by Alpha C et al showed an incidence of impaired wound healing after BSSO of 26%.<sup>30</sup>

Facial edema in the late postoperative period occurred in 10 patients up to 7 months after surgery and mostly healed spontaneously (some required antibiotic therapy or surgical extraction of osteosynthesis material). Facial edema is a common complication of orthognathic surgery in the early postoperative period. All patients were prescribed dexamethasone during surgery and in the early postoperative period. Similar data are reported in the literature.<sup>31</sup>

Speech problems occurred in two patients. In one patient nasal speech occurred after the onset of oroantral fistula and in the other pronunciation problems occurred (possible cause is a change in the position of the tongue reducing the oral cavity).

Sinusitis occurred for the first time after surgery in 2.8% of patients (n=2). Literature states that sinusitis can occur after jaw surgery due to changes in the anatomy of the nasal and paranasal cavities, resulting in changes in sinus homeostasis, with a prevalence between 2 and 16%.<sup>32</sup>

Alopecia occurred in one patient for the first time after surgery. Postoperative alopecia may occur after jaw surgery due to the duration of the operation itself, the use of hypotensive anesthesia and the forces exerting pressure on the head during osteotomy.<sup>33</sup>

Difficulty in chewing occurred in one patient after a period of recovery due to atrophy of the masseter's musculature on the right side. A possible cause is a damage to the motor part of the mandibular nerve during surgery, but that has not been proven in this patient.<sup>34</sup>

In 16.7% of patients (n=12) the material protruded (in the period from 11 days to 1 year after the surgery), and in 23.6% of patients (n=1) the extraction was necessary. A 2020 study conducted by Gómez-Barrachina R et al stated that the frequency of titanium plate removal was 13.4%, and the most common reasons for removal were infection (6.6%) and material protrusion (2.6%).<sup>35</sup> Risk factors are female gender, smoking, and plaques located in the lower jaw.<sup>35</sup>

After surgery, paresthesias occurred in 86.1% of patients (n=62), and the consequences of damage to the sensory branches of the trigeminal nerve remained permanently present in 66.1% of patients (n=41). In most patients, the paresthesias regressed over a period of several weeks to several months, with similar data reported in the literature.<sup>36</sup> Patients in whom the

consequences of damage to the sensory branches of the trigeminal nerve (occasional tingling, tightness, pain, loss of sensation) remain permanently present do not consider them inconvenient. The incidence of inferior alveolar nerve injury differs significantly in studies due to the lack of standardized test methods.<sup>3</sup> Paresthesias in orthognathic surgery are caused by direct or indirect mechanical damage or resection of the nerve during surgery.<sup>36</sup> Nerve injuries can also occur after surgery because of inflammation or bleeding and hematomas around the mandibular canal.<sup>36</sup> Seo et al. state that there is no statistically significant correlation in the frequency of paresthesias between the sexes or types of deformities.<sup>36</sup> There are various studies on ways to prevent and treat paresthesias (application of vitamin B12 complex, application of infrared laser) but no method showed a significant reduction in symptoms in a larger number of patients.<sup>37-38</sup>

27.8% of patients (n=20) had a relapse. Bharti et al. observed relapse at a rate of 24% after sagittal split osteotomy (SSO), also in 6 of the 11 patients who had undergone LFI a relapse rate of 30%.<sup>39</sup> Bailey et al. state that condylar resorption after mandibular advancement makes an important role.<sup>40</sup>

### Conclusion

The majority of patients decided to undergo surgical treatment of jaw deformities due to problems with speech and mastication. The most common complication after surgery are temporary paresthesias, mostly present in the chin and lower lip. Most of the complications, except damage to the sensory branches of the trigeminal nerve, can be successfully treated.

### References

1. Lukšić I et al. Maksilofacijalna kirurgija. 1st ed. Zagreb: Naklada Ljevak; 2019.
2. Mayo Clinic.org, Jaw surgery, 2018 (accessed 13 July 2021).
3. Kim YK. Complications associated with orthognathic surgery. J Korean Assoc Oral Maxillofac Surg 2017;43(1):3-15.
4. Harris M, Chung F. Complications of general anesthesia. Clin Plast Surg 2013;40:503-13.
5. Hwang JM. Analysis of mortality cases related to jaw surgery reported in the mass media: a secondary publication. J Korean Assoc Oral Maxillofac Surg 2016;42:321-324.
6. Steinbacher DM, Kontaxis KL. Does Simultaneous Third Molar Extraction Increase Intraoperative and Perioperative Complications in Orthognathic Surgery? J Craniofac Surg 2016;27:923-6.

7. Tiwari R, Ramees M, Mathew P, Mathai P, Francis M, Jay N. Role of maxillary third molar in le fort i orthognathic surgery: A mini review & case report. Int J Appl Dent Sci 2018;4:280-281.
8. Harris M, Chung F. Complications of general anesthesia. Clin Plast Surg. 2013;40(4):503-13.
9. Schwartz HC. Simultaneous removal of third molars during sagittal split osteotomies: the case against. J Oral Maxillofac Surg 2004;62:1147-9.
10. Mehra P, Castro V, Frietas RZ, Wolford LM. Complications of the mandibular sagittal split ramus osteotomy associated with the presence or absence of third molars. J Oral Maxillofac Surg 2001;59:854-858.
11. Doucet JC, Morrison AD, Davis BR, Robertson CG, Goodday R, Precious DS. Concomitant removal of mandibular third molars during sagittal split osteotomy minimizes neurosensory dysfunction. J Oral Maxillofac Surg 2012;70:2153-63.
12. Bouchard C, Lalancette M. Infections after sagittal split osteotomy: a retrospective analysis of 336 patients. J Oral Maxillofac Surg 2015;73:158-161.
13. Sasaki R, Yao CF, Chen YA, Lin CH, Chen YR. Concomitant Third Molar Removal During Sagittal Split Osteotomy of the Mandible. J Craniofac Surg 2016;27e:34-6.
14. Brons S, Becking AG, Tuinzing DB. Value of informed consent in surgical orthodontics. J Oral Maxillofac Surg 2009;67:1021-1025.
15. Takatsuji H, Kobayashi T, Kojima T et al. Effects of orthognathic surgery on psychological status of patients with jaw deformities. Int J Oral Maxillofac Surg 2015;44:1125-30.
16. Türker N, Varol A, Ogel K, Basa S. Perceptions of preoperative expectations and postoperative outcomes from orthognathic surgery: part I: Turkish female patients. Int J Oral Maxillofac Surg 2008;37:710-5.
17. Vofs.com.au[Internet]. No Chew Diet. [updated 10.05.2021.;quoted 17.05.2021.]. Available on: <https://vofs.com.au/>
18. Hammond D, Williams RW, Juj K, O'Connell S, Isherwood G, Hammond N. Weight loss in orthognathic surgery: a clinical study. J Orthod 2014;42:220-8.
19. Worrall SF. Changes in weight and body composition after orthognathic surgery and jaw fractures: a comparison of miniplates and intermaxillary fixation. Br J Oral Maxillofac Surg 1994;32:289-292.
20. Phillips C, Brookes CD, Rich J, Arbon J, Turvey TA. Postoperative nausea and vomiting following orthognathic surgery. Int J Oral Maxillofac Surg 2015; 44:745-51.
21. Varon J, Marik PE. Perioperative hypertension management. Vasc Health Risk Manag 2008;4:615-627.
22. Bouchard C, Chiniara G, Valcourt AC. Intraoperative Hypertensive Crisis Secondary to an Undiagnosed Pheochromocytoma During Orthognathic Surgery: A Case Report. J Oral Maxillofac Surg 2014;72:672-5.
23. Mozos I, Urechescu H, Pricop C, Banu A, Vekic I, Pricop M. Blood pressure changes during maxillofacial



- surgery. *J Hypertens* 2018;36:e 269.
24. Sousa CS, Turrini RNT. Complications in orthognathic surgery: A comprehensive review. *J Oral Maxillofac Surg Med Pathol* 2012;24:67-74.
  25. Cousin AS, Bouletreau P, Giai J, Ibrahim B, Louvrier A, Sigoux N. Severity and long- term complications of surgical site infections after orthognathic surgery: a retrospective study. *Sci Rep* 2020;10:12015.
  26. Posnick JC, Choi E, Chavda A..Surgical Site Infections Following Bimaxillary Orthognathic, Osseous Genioplasty, and Intranasal Surgery: A Retrospective Cohort Study. *Oral Maxillofac Surg* 2017;75:584-595.
  27. Gu G, Nagata J, Suto M. et al. Hyoid position, pharyngeal airway and head posture in relation to relapse after the mandibular setback in skeletal Class III. *Clin Orthod Res* 2000;3:67-77.
  28. Weinspach K, Staufenbiel I, Günay H, Geurtsen W, Schwestka-Polly R, Demling AP. Influence of orthognathic surgery on periodontal tissues: short-term results. *J Orofac Orthop* 2011;72(4):279.
  29. Lee UL, Lee EJ, Seo HY, Han SH, Choi WC, Choi YJ. Prevalence and risk factors of tooth discolouration after orthognathic surgery: a retrospective study of 1455 patients. *Int J Oral Maxillofac Surg* 2016;45:1464-70.
  30. Alpha C, O’Ryan F, Silva A, Poor D. The incidence of postoperative wound healing problems following sagittal ramus osteotomies stabilized with miniplates and monocortical screws. *J Oral Maxillofac Surg* 2006;64:659-68.
  31. Semper-Hogg W, Fuessinger MA, Dirlwanger TW, Cornelius CP, Metzger MC. The influence of dexamethasone on postoperative swelling and neurosensory disturbances after orthognathic surgery: a randomized controlled clinical trial. *Head Face Med* 2017;13:19.
  32. Procacci P, Lanaro L, Trevisiol L. et al. Is post orthognathic maxillary sinusitis related to sino-nasal anatomical alterations? *J Craniomaxillofac Surg* 2019;47:876-882.
  33. Davies KE, Yesudian P. Pressure alopecia. *Int J Trichology* 2012;4:64-68.
  34. Ariji Y, Fuwa N, Tachibana H, Ariji E. Denervation atrophy of the masticatory muscles in a patient with nasopharyngeal cancer: MR examinations before and after radiotherapy. *Dentomaxillofac Radiol* 2002;31:204-8.
  35. Gómez-Barrachina R, Montiel-Company JM, García-Sanz V, Almerich-Silla JM, Paredes-Gallardo V, Bellot-Arcís C. Titanium plate removal in orthognathic surgery: prevalence, causes and risk factors. A systematic literature review and meta-analysis. *Int J Oral Maxillofac Surg* 2020;49:770-778.
  36. Seo K, Tanaka Y, Terumitsu M, Someya G. Characterization of different paresthesias following orthognathic surgery of the mandible. *J Oral Maxillofac Surg* 2005;63:298- 303.
  37. Travassos Prazeres LD, Muniz YV, Barros KM, Gerbi ME, Laureano Filho JR. Effect of infrared laser in the prevention and treatment of paresthesia in orthognathic surgery. *J Craniofac Surg* 2013;24:708-11.
  38. Lee CH, Lee BS, Choi BJ et al. Recovery of inferior alveolar nerve injury after bilateral sagittal split ramus osteotomy (BSSRO): a retrospective study. *Maxillofac Plast Reconstr Surg* 2016; 38:25.
  39. Wasan B, Mohindru K, Shetty V, Shilpa S. Evaluation Of Relapse In Orthognathic Surgery: An Original Research. *Eur J Mol Clin Med* 2020;7:3210-3215.
  40. Bailey LTJ, Cevidanis LHS, Proffit WR. Stability and predictability of orthognathic surgery. *Am J Orthod Dentofacial Orthop* 2004;126:273-7.