

Left ventricular benign tumors commonly misdiagnosed as thrombus

Levicki, Rea; Barišić, Ivan; Raštegorac, Ile; Petranović, Jurica; Dujmović, Vladimir; Lovrić Benčić, Martina

Conference presentation / Izlaganje na skupu

Permanent link / Trajna poveznica: <https://um.nsk.hr/um:nbn:hr:267:011058>

Rights / Prava: [In copyright](#)/[Zaštićeno autorskim pravom](#).

Download date / Datum preuzimanja: **2025-02-01**

Repository / Repozitorij:

[Repository of General County Hospital Požega](#)

Left ventricular benign tumors commonly misdiagnosed as thrombus

Rea Levicki^{1*},
Ivan Barišić¹,
Ile Raštegorac¹,
Jurica Petranović¹,
Vladimir Dujmović¹,
Martina Lovrić
Bencić²

¹Požega General Hospital,
Požega, Croatia

²University Hospital Centre
Zagreb, Zagreb, Croatia

KEYWORDS: heart tumor, ventricular mass, fibroma.

CITATION: *Cardiol Croat.* 2024;19(3-4):139-40. | <https://doi.org/10.15836/ccar2024.139>

***ADDRESS FOR CORRESPONDENCE:** Rea Levicki, Opća županijska bolnica Požega, Osječka 107, HR-34000 Požega, Croatia. / Phone number: +385-98-550-309 / E-mail: rlevicki@gmail.com

ORCID: Rea Levicki, <https://orcid.org/0000-0003-3687-1310> • Ivan Barišić, <https://orcid.org/0000-0001-7397-7582>
Ile Raštegorac, <https://orcid.org/0000-0002-2773-0957> • Jurica Petranović, <https://orcid.org/0000-0002-7129-0266>
Vladimir Dujmović, <https://orcid.org/0000-0001-6545-9283> • Martina Lovrić Bencić, <https://orcid.org/0000-0001-8446-6120>

Introduction: The most common left ventricular (LV) mass is thrombus.¹ It is important to differentiate LV thrombus from common benign tumors; myxomas, papillary fibroelastomas and lipomas but also some rare tumors; rhabdomyomas and fibromas or malignant cardiac sarcoma.^{2,3}

Case report: 59-year-old male patient presented with intermittent chest pain and worsening shortness of breath and orthopnea. Four years ago he had myocardial infarction of the anteroseptal region with remaining hypokinesia of the apical anterior wall and apex dilatation. Transthoracic echocardiography showed estimated left ventricular ejection fraction 48%, hypokinesia of the apical anterior wall and apex dilatation with homogeneous mass visualized on apical part of the lateral left ventricular wall and it was difficult to differentiate a thrombus from LV tumor. 4D transesophageal echocardiography was performed and it showed LV mass measuring 1.5cm×1.9cm attached to the apical part of the lateral left ventricular wall on two sides that resembled a pedunculated tumor (**Figure 1** and **Figure 2**). It was homogenous and noncalcified, nonmobile with echodensity similar to the myocardium. On cardiac computed tomography (CT) LV mass showed features of benign tumor (size <5cm, single lesion, pedunculated, with absent enhancement, with smooth, well-defined margins, with no signs of invasion, metastasis, pericardial effusion or calcification), most probably a fibroma (**Figure 3**). Significant coronary artery stenoses were excluded on ct coronarography. With chronic therapy correction and optimal heart failure therapy patient was asymptomatic. On repeated transesophageal echocardiography during 6 months period LV mass remained the same size. Patient was examined by cardiac surgeon and follow up was recommended, considering unchanged size and echocardiographic and CT features of the tumor, surgical treatment was not indicated. Cardiac magnetic resonance imaging (MR) is planned to confirm the diagnosis.

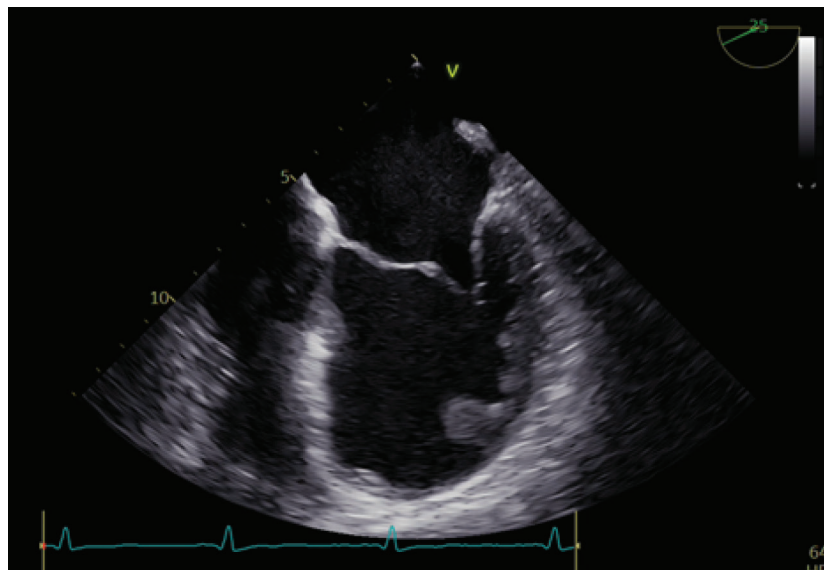


FIGURE 1. Left ventricular tumor on transesophageal echocardiography.

RECEIVED:
October 8, 2023

ACCEPTED:
October 27, 2023



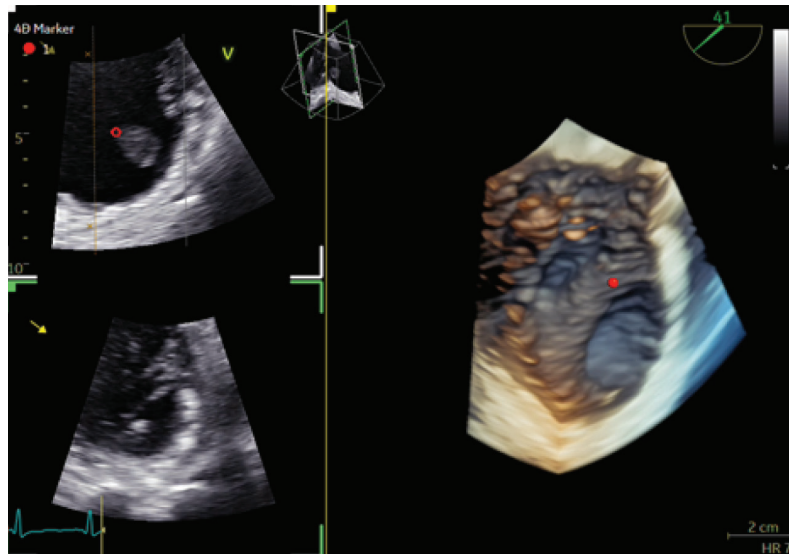


FIGURE 2. Left ventricular tumor on 4D transesophageal echocardiography.

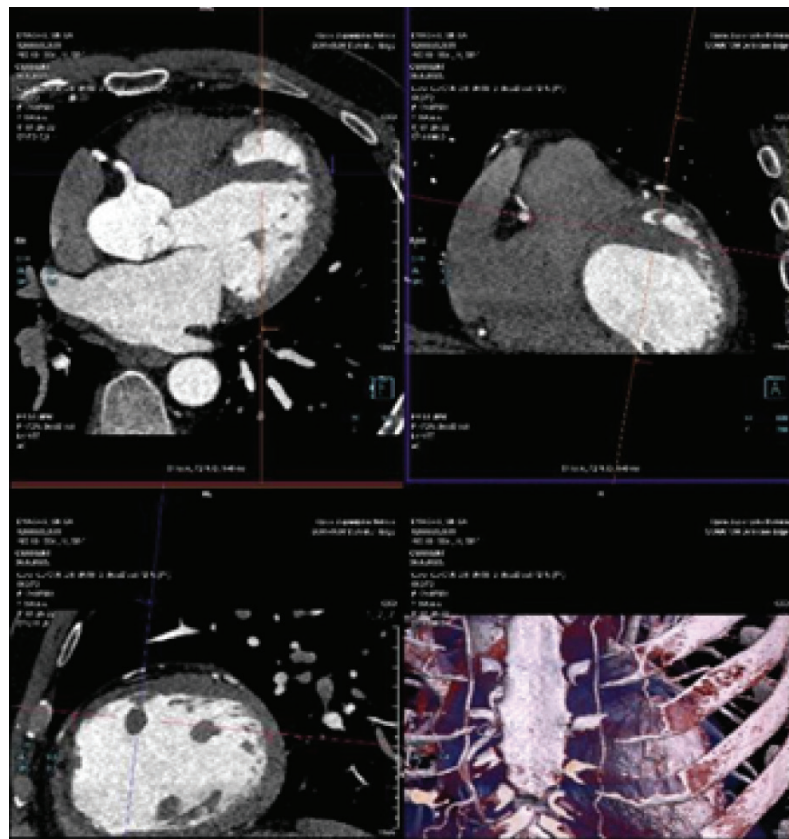


FIGURE 3. Left ventricular tumor on cardiac computed tomography.

Conclusion: Echocardiography is an important tool in intracardiac mass evaluation and identification of the LV mass size, shape, mobility and attachment is important do differentiate LV thrombus from tumors. An intracardiac mass should be assessed in multiple views, both during systole and diastole. Cardiac MR or CT should be used to confirm the diagnosis.

LITERATURE

1. Khan WJ, Asif M, Nadeem I, Aslam S, Chowdhury MA. Diagnostic and Therapeutic Challenges Associated With Left Ventricular Tumors. *Cureus*. 2023 Mar 20;15(3):e36443. <https://doi.org/10.7759/cureus.36443>
2. Bruce CJ. Cardiac tumours: diagnosis and management. *Heart*. 2011 Jan;97(2):151-60. <https://doi.org/10.1136/hrt.2009.186320>
3. Dinesh Kumar US, Shetty SP, Sujay KR, Wali M. Left ventricular mass: A tumor or a thrombus diagnostic dilemma. *Ann Card Anaesth*. 2016 Oct-Dec;19(4):728-732. <https://doi.org/10.4103/0971-9784.191551>