

Left ventricular non-compaction cardiomyopathy in adult congenital heart disease tetralogy of Fallot

Levicki, Rea; Barišić, Ivan; Raštegorac, Ile; Petranović, Jurica; Dujmović, Vladimir; Lovrić Benčić, Martina

Conference presentation / Izlaganje na skupu

Permanent link / Trajna poveznica: <https://um.nsk.hr/um:nbn:hr:267:308083>

Rights / Prava: [In copyright](#)/[Zaštićeno autorskim pravom](#).

Download date / Datum preuzimanja: **2024-11-21**

Repository / Repozitorij:

[Repository of General County Hospital Požega](#)

Left ventricular non-compaction cardiomyopathy in adult congenital heart disease tetralogy of Fallot

Rea Levicki^{1*},
Ivan Barišić¹,
Matias Trbušić²,
Ozren Vinter²,
Jurica Petranović¹,
Ile Raštegorec¹,
Vladimir Dujmović¹,
Martina Lovrić
Benčić³

¹Požega General Hospital,
Požega, Croatia

²University Hospital Centre
"Sestre milosrdnice", Zagreb,
Croatia

³University Hospital Centre
Zagreb, Zagreb, Croatia

KEYWORDS: Tetralogy of Fallot, left ventricular non-compaction cardiomyopathy, adult congenital heart disease.

CITATION: *Cardiol Croat.* 2024;19(3-4):141-2. | <https://doi.org/10.15836/ccar2024.141>

***ADDRESS FOR CORRESPONDENCE:** Rea Levicki, Opća županijska bolnica Požega, Osječka 107, HR-34000 Požega, Croatia. / Phone number: +385-98-550-309 / E-mail: rlevicki@gmail.com

ORCID: Rea Levicki, <https://orcid.org/0000-0003-3687-1310> • Ivan Barišić, <https://orcid.org/0000-0001-7397-7582>
Matias Trbušić, <https://orcid.org/0000-0001-9428-454X> • Ozren Vinter, <https://orcid.org/0000-0002-4236-7594>
Jurica Petranović, <https://orcid.org/0000-0002-7129-0266> • Ile Raštegorec, <https://orcid.org/0000-0002-2773-0957>
Vladimir Dujmović, <https://orcid.org/0000-0001-6545-9283> • Martina Lovrić Benčić, <https://orcid.org/0000-0001-8446-6120>

Introduction: Left ventricular non-compaction cardiomyopathy (LVNC) is defined with excessive trabeculations of the left ventricle and is known to be genetically determined. Several studies suggest that LVNC is associated with adult congenital heart disease (ACHD), especially Ebstein anomaly and infrequently with left ventricular outflow obstruction (bicuspid aortic valve), coarctation of the aorta and tetralogy of Fallot.¹ There are only a few cases in a world of adults with tetralogy of Fallot and combined LVNC described, and the prognosis of this condition is still unclear.^{2,3}

Case report: 63-years-old patient was admitted to the hospital because of the first clinical manifestation of a heart failure. In his previous medical history, it was known that a patient had tetralogy of Fallot diagnosed in a childhood and he underwent cardiac surgery with total congenital heart disease repair when he was 29 years old. Echocardiography (TTE and TEE) demonstrated dilated left ventricle with asymmetric hypertrophy of the apical wall (25mm) and left ventricular hypertrabeculation (**Figure 1**) with ratio between non-compacted and compacted layer approximately >2, with globally reduced contractility and reduced ejection fraction (LVEF 25%). Coronary angiography and right heart catheterization were performed, and coronary artery disease was excluded, max systolic pulmonary artery pressure 38mmHg. Cardiac magnetic resonance imaging showed hypertrabeculation of both left and right ventricle in segments 7, 11, 12, 13, 14, 16 with ratio between non-compacted and compacted layer approximately >2,3, globally reduced contractility with fibrosis of basal anteroseptal wall, reduced left and right ventricular ejection fraction, LVEF 25%, RVEF 35%, late gadolinium enhancement demonstrated pathological contrast imbibition of a "mid wall" type in segment 2 (non-ischemic etiology) (**Figure 2** and **Figure 3**). Patient was initially treated with diuretics and optimal heart failure therapy and 3 months later, with satisfied criteria for implantation, cardiac resynchronization therapy defibrillator was implanted. Patient is referred to a heart team for cardiac transplantation evaluation.

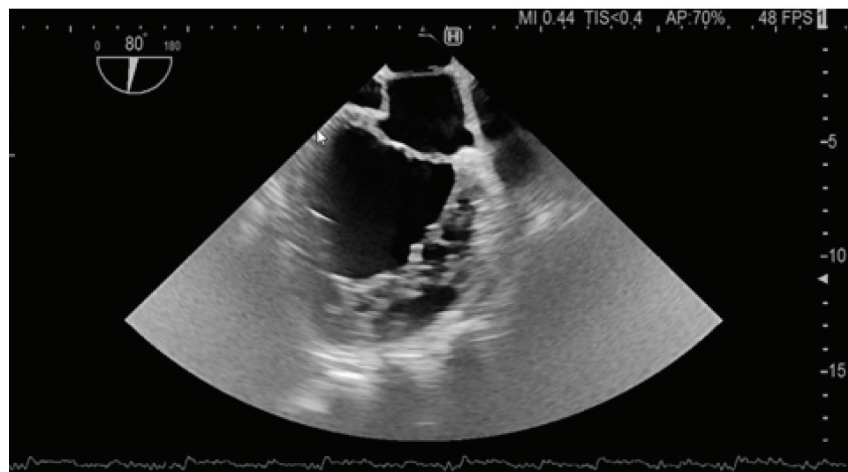


FIGURE 1. Left ventricular hypertrabeculation on transesophageal echocardiography.

RECEIVED:
October 8, 2023

ACCEPTED:
October 27, 2023



